# MAJOR CONNECTORS IN REMOVABLE PARTIAL DENTURES

# Learning objective

- By the end of this session student should know about the different types of major connectors , their specifications and application.

# contents


- Introduction
- Functions of major connectors
- Guidelines for design and location of major connector
- Maxillary major connectors
- Design of maxillary major connector
- Mandibular major connectors
- Design of mandibular major connector
- Minor connectors
- Selection of major connector
- References

# Introduction

- A major connector is the component of the partial denture that connects the parts of the prosthesis located on one side of the arch with those on the opposite side.

# Functions

- Unification of the major parts of the prosthesis
- Distribution of the applied force throughout the arch to selected teeth and tissue
- Minimization of torque to the teeth
- A rigid major connector will limit movement possibilities by acting as a counteracting lever. ( Cross arch stability)

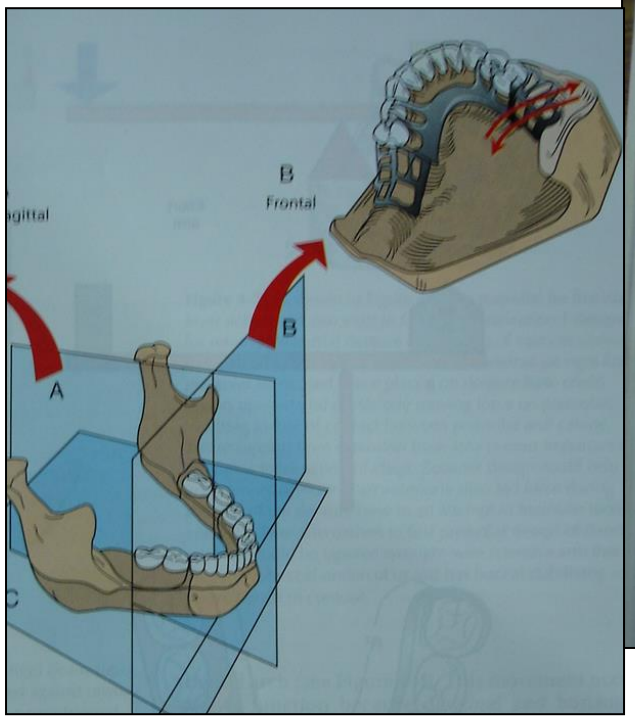


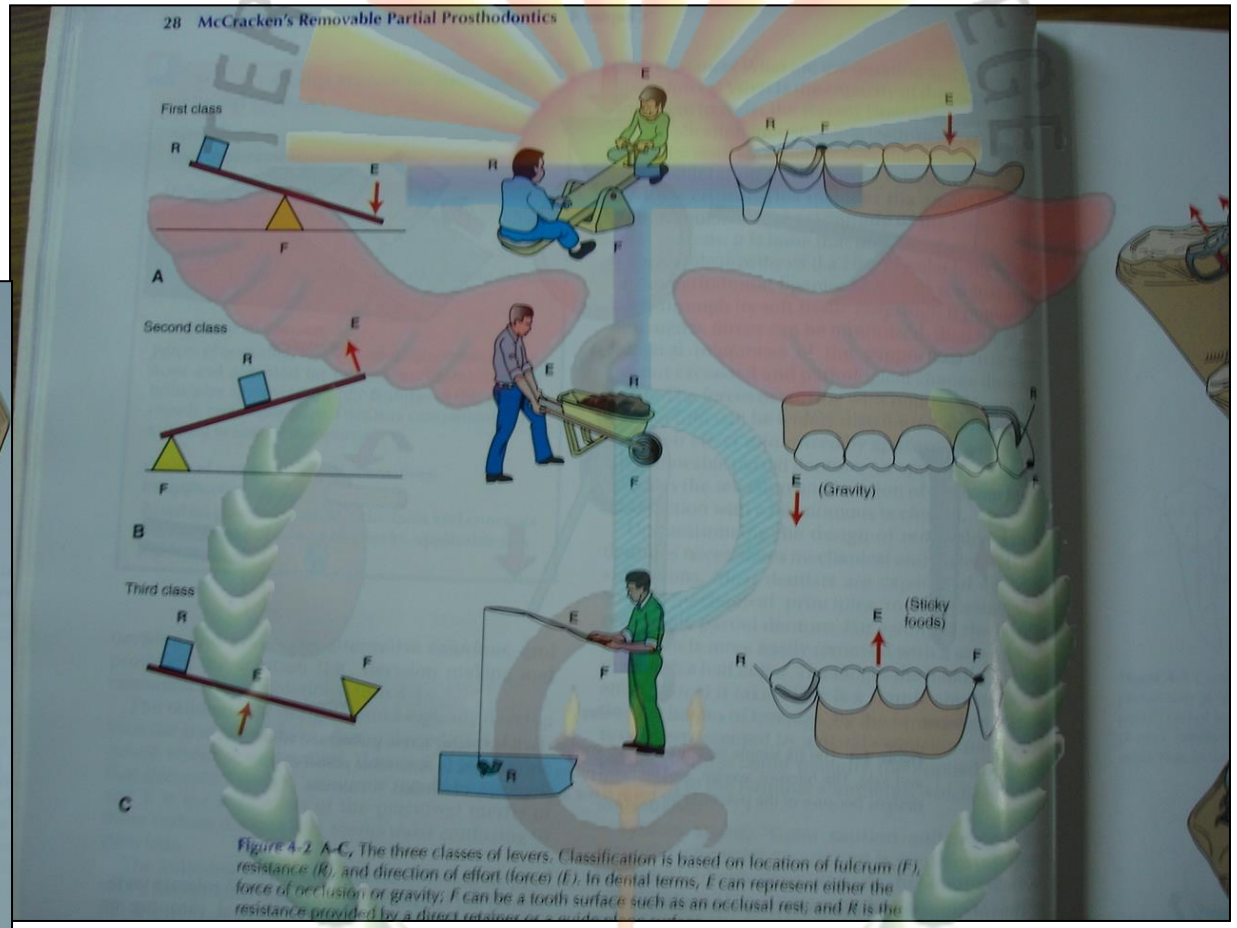


Figure 4-2 A-C, The three classes of levers. Classification is based on location of fulcrum (F), resistance (R), and direction of effort (force) (E). In dental terms, E can represent either the force of occlusion or gravity; F can be a tooth surface such as an occlusal rest; and R is the resistance provided by a direct retainer or a rigid

# Guidelines for design and location of major connector

1. Major connectors should be free of movable tissue.
2. Impingement of gingival tissue should be avoided.
3. Bony and soft tissue prominences should be avoided during placement and removal.
4. Relief should be provided beneath a major connector to prevent its settling into areas of possible interference.
5. Major connectors should be located and/ or relieved to prevent impingement of tissue because the distal extension denture rotates in function

**Figure 5-3** **A,** Lingual bar major connector should be l margins and more if possible. The vertical height of a fi 4 mm for strength and rigidity. If less than 8 mm exists b floor of mouth, a linguoplate **(B),** a sublingual bar **(C),** a major connector. Relief is provided for soft tissue und connector and any location where the framework cros border of mandibular major connectors should be gen a sharp edge.

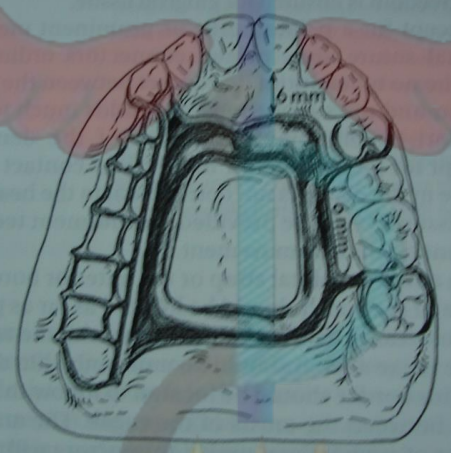


**Figure 5-4** Palatal major connector should be located at least 6 mm away from gingival margins and parallel to their mean curvature. All adjoining minor connectors should cross gingival tissues abruptly and should join major connectors at nearly a right angle.



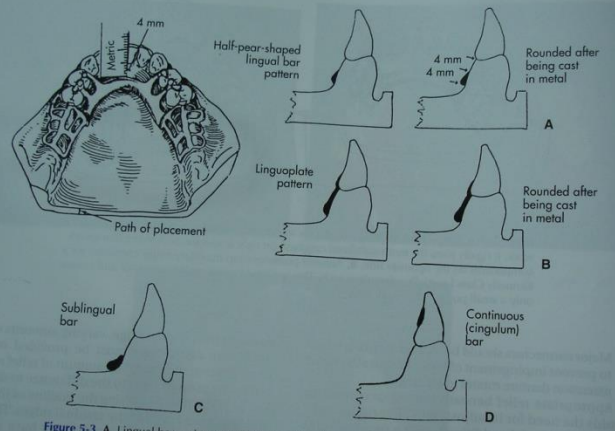


**Figure 5-3** **A,** Lingual bar major connector should be located at least 4 mm inferior to gingival margins and more if possible. The vertical height of a finished lingual bar should be at least 4 mm for strength and rigidity. If less than 8 mm exists between gingival margins and movable floor of mouth, a linguoplate **(B),** a sublingual bar **(C),** or a continuous bar **(D)** is preferred as a major connector. Relief is provided for soft tissue under all portions of the mandibular major connector and any location where the framework crosses the marginal gingiva. The inferior border of mandibular major connectors should be gently rounded after being cast to eliminate a sharp edge.

6. Beading of maxillary cast:

- To transfer the major connector design
- To provide visible finish line
- To insure intimate tissue contact

# Maxillary major connectors

- The six types of maxillary major connectors are

1. Single palatal strap
2. anterior and posterior palatal strap
3. Palatal plate type connector
4. U shaped palatal connector
5. Single palatal bar
6. Anterior–posterior palatal bar

# Single palatal strap

- Indications
  - Kennedy's class III
  - Short span toothsupported bilateral edentulous areas.
  - May be used in tooth-supported unilateral edentulous situations with provision for cross-arch attachment.
- Contraindications
  - In distal extension cases (Bilateral)
  - In cases where distal extension bases are connected with anterior replacements.


**Figure 5-18** Maxillary major connectors: **A,** Single palatal strap. **B,** Anterior-posterior palatal strap. **C,** Palatal plate. **D,** U-shaped. **E,** Single palatal bar. **F,** Anterior-posterior palatal bars.

relief, and/or locate the connector far enough away from the gingival margin to avoid any possible obstruction of blood supply and entrapment of food

right angles to the major connector. Creating a sharp, angular form on any portion of a palatal connector should be avoided, and all borders should be tapered

# Combination anterior and posterior palatal strap

- Guidelines for design
  - Posterior strap 8 mm wide
  - Posterior extension as far as possible
- Indications
  - Can be used in almost all maxillary partial denture designs
- Contraindication
  - Inoperable maxillary torus, lying posterior to soft palate


**Figure 5-18** Maxillary major connectors: **A,** Single palatal strap. **B,** Anterior-posterior palatal strap. **C,** Palatal plate. **D,** U-shaped. **E,** Single palatal bar. **F,** Anterior-posterior palatal bars.

relief, and/or locate the connector far enough away from the gingival margin to avoid any possible obstruction of blood supply and entrapment of food

right angles to the major connector. Creating a sharp, angular form on any portion of a palatal connector should be avoided, and all borders should be tapered

# Palatal plate type connector

- maxillary major connector covering one half or more of the hard palate.
- Advantages
  - Uniformly thin
  - Surface irregularities
  - Interfacial surface tension
- Indication
  - Maxillary bilateral distal extension cases
- Contraindication
  - Inoperable maxillary torus

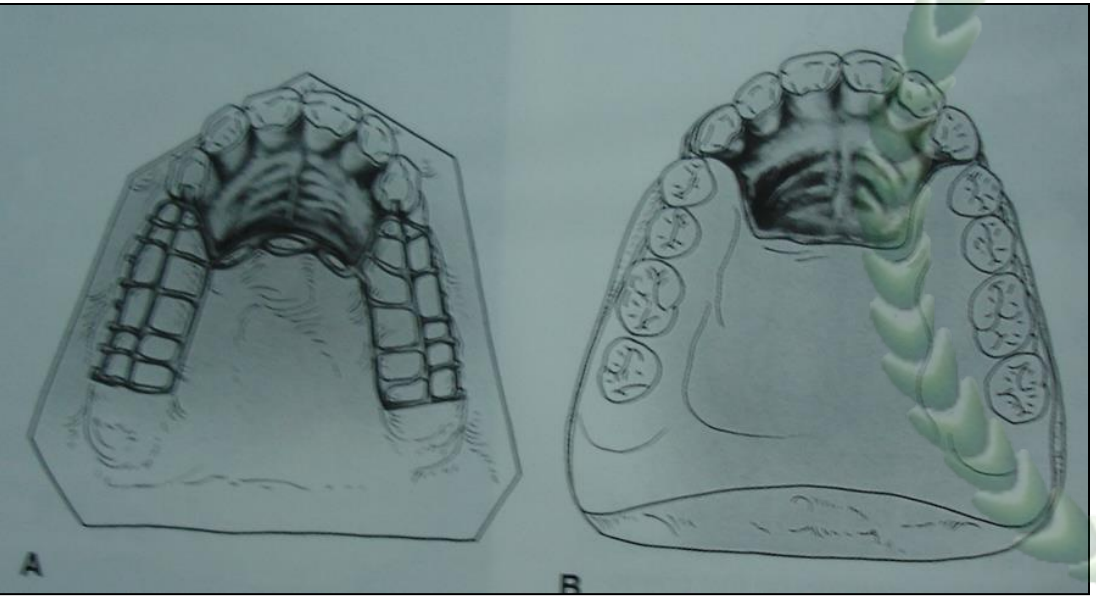



Figure 5-18 Maxillary major connectors: **A,** Single palatal strap. **B,** Anterior-posterior palatal strap. **C,** Palatal plate. **D,** U-shaped. **E,** Single palatal bar. **F,** Anterior-posterior palatal bars.

relief, and/or locate the connector far enough away from the gingival margin to avoid any possible restriction of blood supply and entrapment of food

right angles to the major connector. Creating a sharp, angular form on any portion of a palatal connector should be avoided, and all borders should be tapered

1. Plate of varying width that covers the area between two or more edentulous areas.
2. Complete or partial cast plate that extends posteriorly to the junction of the hard and soft palates
3. Anterior palatal connector with a provision for extending an acrylic resin denture base posteriorly

# U shaped palatal connector

- Least desirable of maxillary connectors
- Indications
  - Large inoperable maxillary torus
  - Several anterior teeth
- Contraindications
  - Distal extension cases
- Disadvantages
  - Lack of rigidity
  - Fails to provide good support
  - Hindrance to tongue


**Figure 5-18** Maxillary major connectors: **A,** Single palatal strap. **B,** Anterior-posterior palatal strap. **C,** Palatal plate. **D,** U-shaped. **E,** Single palatal bar. **F,** Anterior-posterior palatal bars.

relief, and/or locate the connector far enough away from the gingival margin to avoid any possible obstruction of blood supply and entrapment of food

right angles to the major connector. Creating a sharp, angular form on any portion of a palatal connector should be avoided, and all borders should be tapered

# Single palatal bar

- Rigid enough to provide support and cross arch stabilization
- Too bulky and objectionable to the patient


**Figure 5-18** Maxillary major connectors: **A,** Single palatal strap. **B,** Anterior-posterior palatal strap. **C,** Palatal plate. **D,** U-shaped. **E,** Single palatal bar. **F,** Anterior-posterior palatal bars.

relief, and/or locate the connector far enough away from the gingival margin to avoid any possible obstruction of blood supply and entrapment of food

right angles to the major connector. Creating a sharp, angular form on any portion of a palatal connector should be avoided, and all borders should be tapered

# Anterior–posterior palatal bar

- It exhibits the same disadvantages as the single palatal bar
- To be sufficiently rigid and to provide the needed support and stability, the connectors could be bulky and interfere with tongue function


**Figure 5-18** Maxillary major connectors: **A,** Single palatal strap. **B,** Anterior-posterior palatal strap. **C,** Palatal plate. **D,** U-shaped. **E,** Single palatal bar. **F,** Anterior-posterior palatal bars.

relief, and/or locate the connector far enough away from the gingival margin to avoid any possible obstruction of blood supply and entrapment of food

right angles to the major connector. Creating a sharp, angular form on any portion of a palatal connector should be avoided, and all borders should be tapered

# Design of maxillary major connector

- In 1953 Blatterfein described a systematic approach to designing maxillary major connectors

1. Outline of primary bearing areas
2. Outline of nonbearing areas
3. Outline of connector areas
4. Selection of connector type
   A. Mouth comfort
   B. Rigidity
   C. Location of denture bases
   D. Indirect retention
5. unification

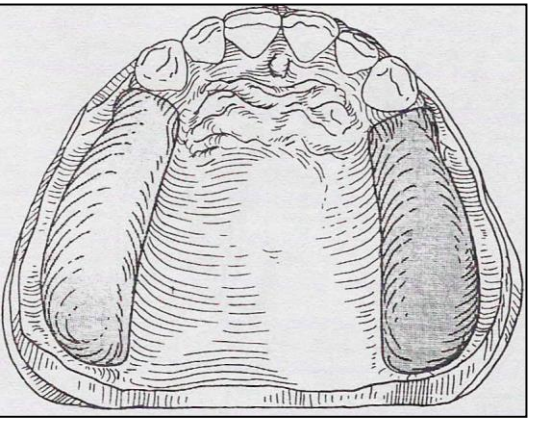

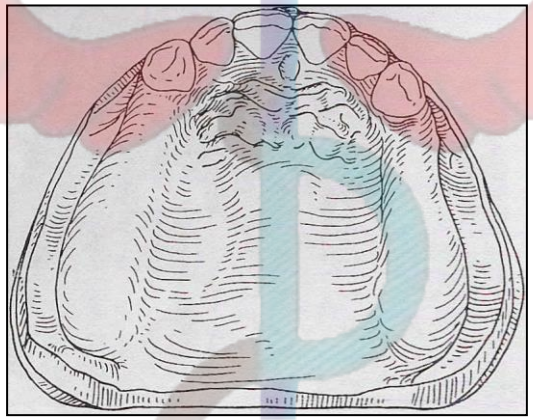

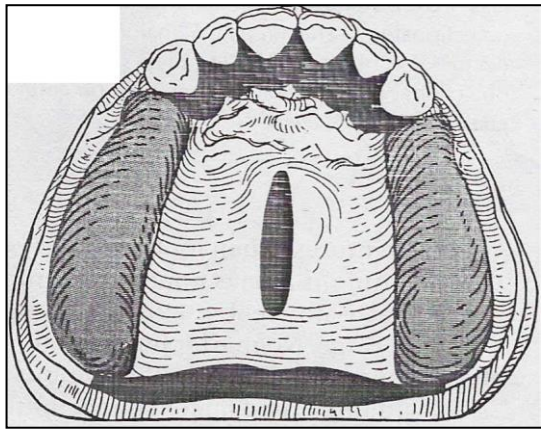

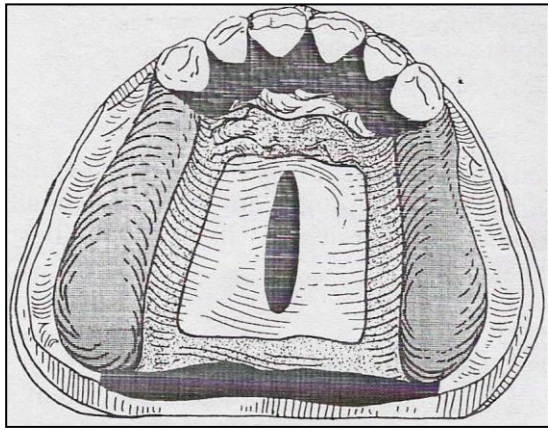

# Mandibular major connectors

- The six types of madibular major connectors are:

1. Lingual bar
2. Linguoplate
3. Sublingual bar
4. Lingual bar with cingulum bar
5. Cingulum bar (continuous bar)
6. Labial bar

# Lingual bar

- Half pear shape, located above moving tissue but as far below the gingival tissue.
- Clinically acceptable methods to determine the relative height of the floor of the mouth to locate the inferior border of a lingual mandibular major connector.
  - Use of periodontal probe
  - use an individualized impression tray

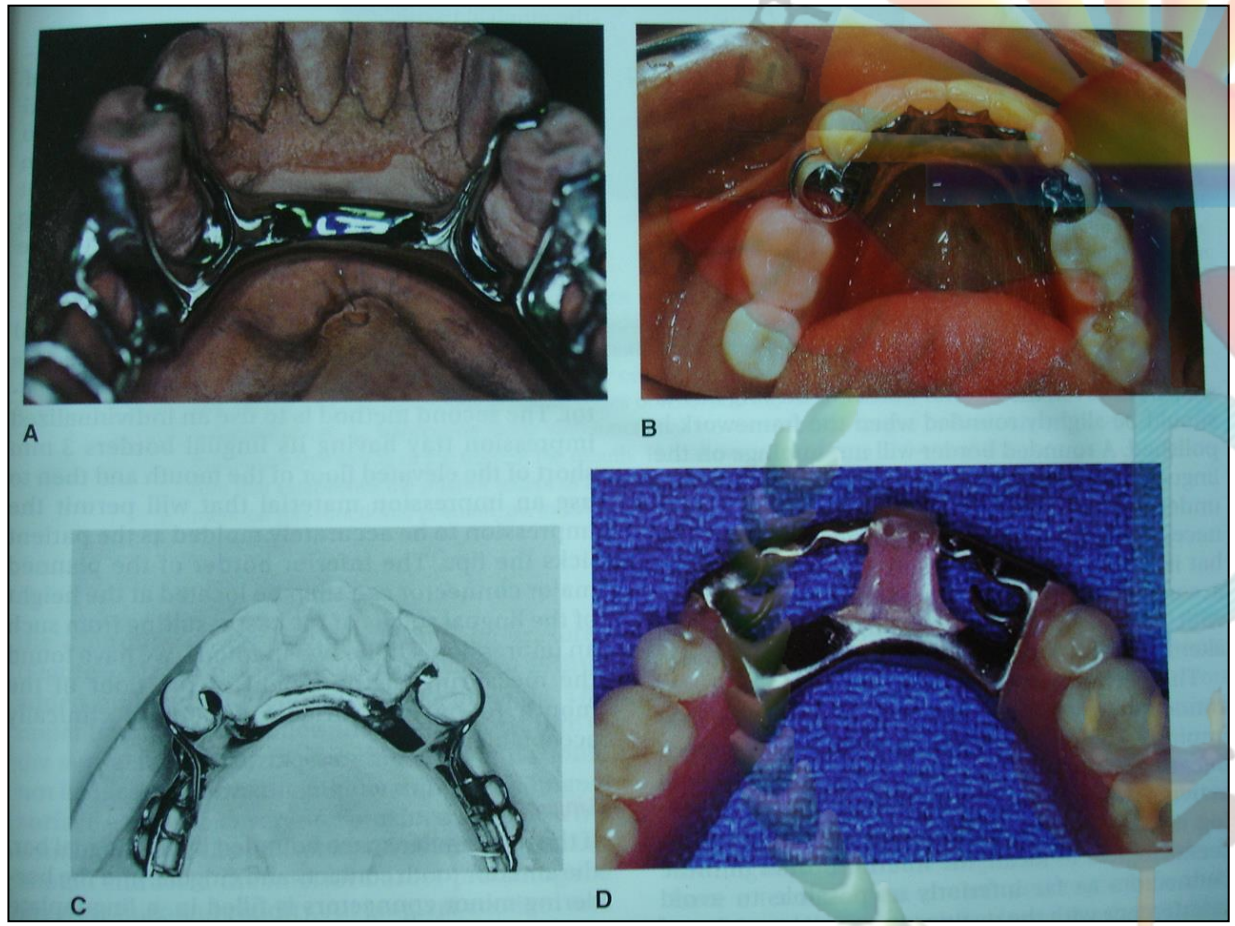


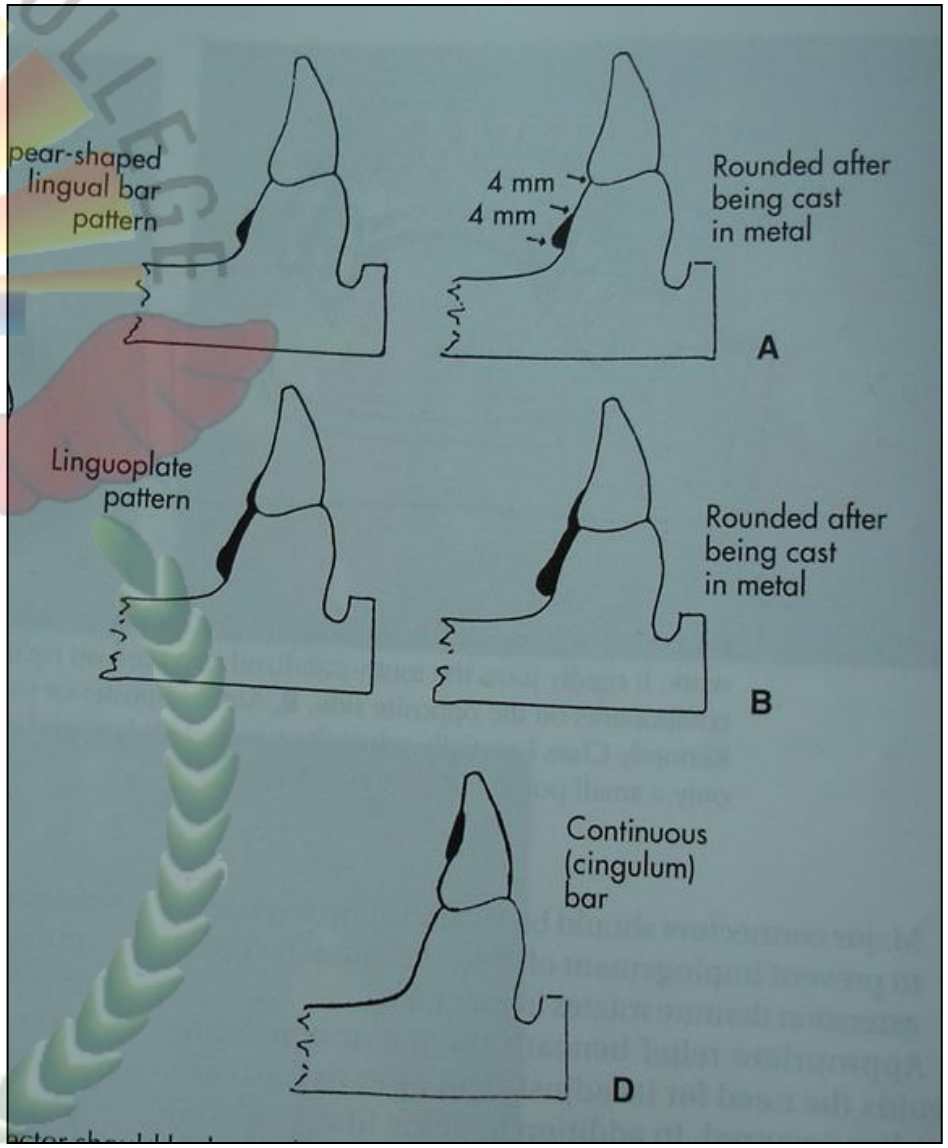

A

B

- Indications
  - Where ever sufficient space exist between the slightly elevated alveolar sulcus and the lingual gingival tissue.
- Contraindication
  - Cases with mandibular tori
  - Reduced alveolo lingual sulcus

# Linguoplate

- It is a lingual bar with a portion of major connector covering the lingual surface of natural teeth.
- Follow the natural curves
- Gingival crevices and deep embrasures must be blocked
- Terminal rest at each end

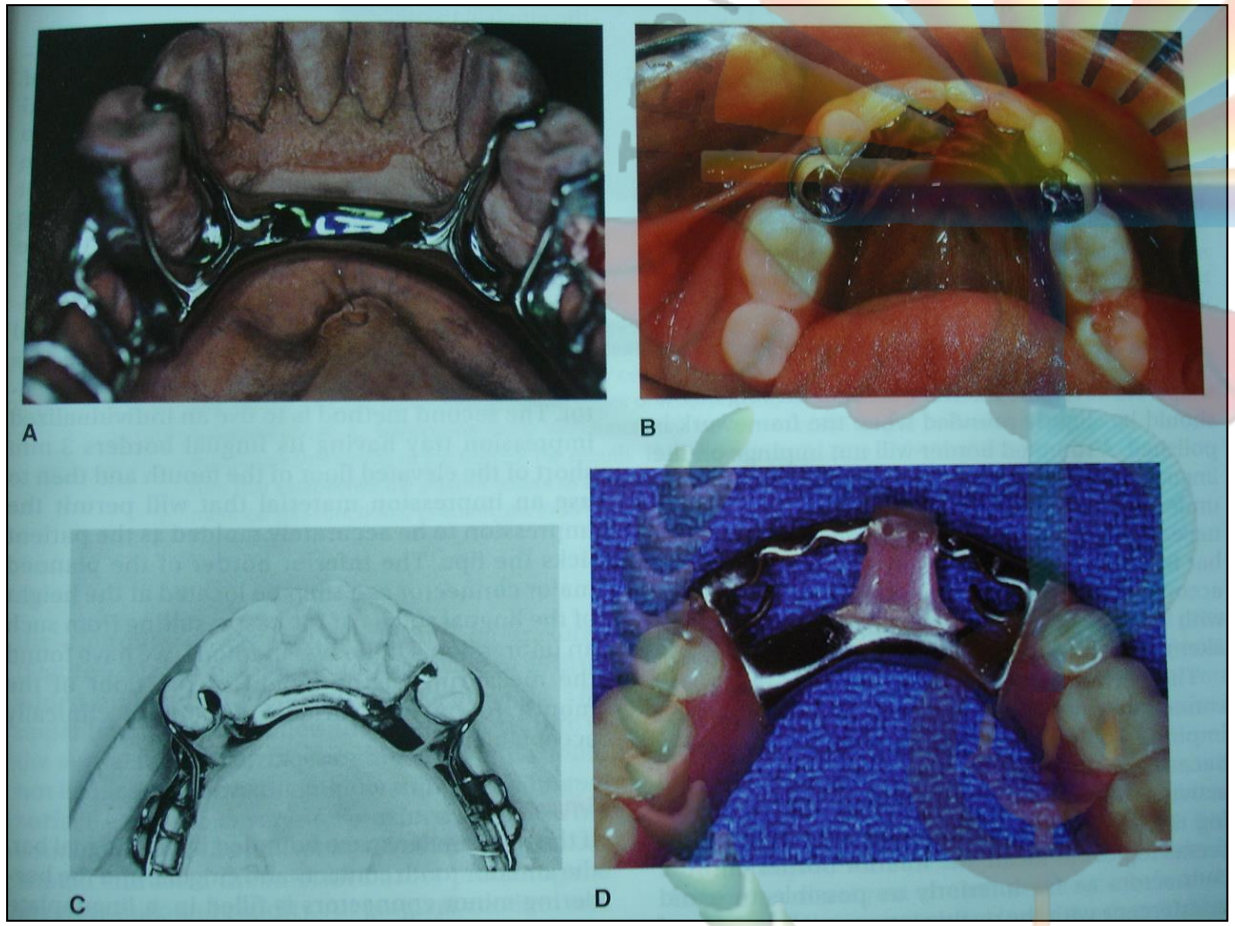




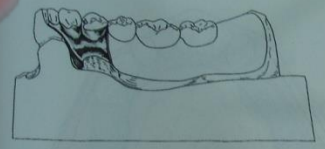

**Figure 5-11** Sagittal section through linguoplate demonstrating basic half-pear-shaped inferior border with metallic apron extending superiorly. Extension of linguoplate to height of contour on premolar was accomplished to enclose a rather large triangular interproximal space inferior to contact point between canine and premolar. Such spaces may often be bridged to eliminate obvious food traps. Relief is provided for soft tissue under all portions of the mandibular major connector and any location where the framework crosses the marginal gingiva.

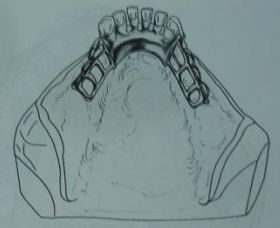

**Figure 5-12** Interrupted linguoplate in presence of interproximal spaces.

the remaining teeth or for horizontal stabilizing of the prosthesis, or for both, small rectangular spaces sometimes remain. Tissue response to such small spaces is better when bridged with an apron than when it is left open. Generally the apron is used to avoid gingival irritation or entrapment of food debris or to cover generously relieved areas that would be irritating to the tongue (Figure 5-11).

Sometimes a dentist is faced with a clinical situa-

### *Sublingual Bar*

A modification of the lingual bar that has been demonstrated to be useful when the height of the floor of the mouth does not allow placement of the superior border of the bar at least 4 mm below the free gingival margin is the sublingual bar. The bar shape remains essentially the same as that of a lingual bar, but placement is inferior and posterior to the usual placement of a lingual bar, lying over and parallel to the anterior floor

- Indications
  - Lingual frenum is high or space available is limited
  - In class I situations with excessive resorption of residual ridges
  - For stabilizing periodontally weakened teeth
  - In cases of future replacement of one or more anterior teeth.
- Contraindications
  - Patients with poor oral hygiene

# Sublingual bar

- A modification of the lingual bar when the height of the floor of the mouth does not allow placement of the superior border of the bar at least 4 mm below the free gingival margin.
- Indications
  - Non interfering lingual frenum
  - Anterior lingual undercut
- contraindications
  - Interfering lingual tori
  - High attachment of lingual frenum
  - Interference with elevation of floor of mouth

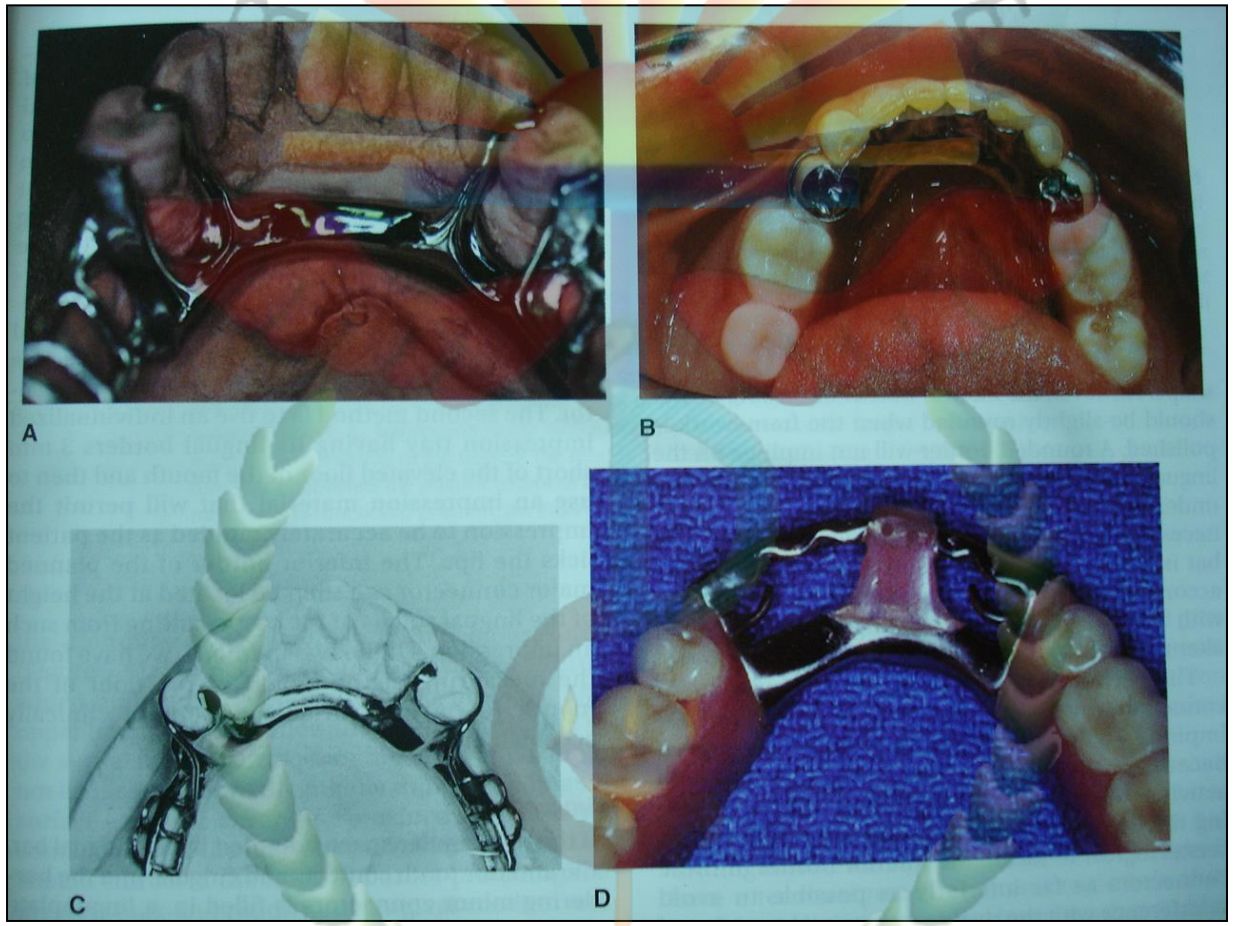

# Lingual bar with cingulum bar

- Also called as kennedy bar.
- Advantages
  - Provide indirect retention
  - Free flow of saliva is permitted
- Disadvantages
  - Tongue annoyance
  - Food entrapment

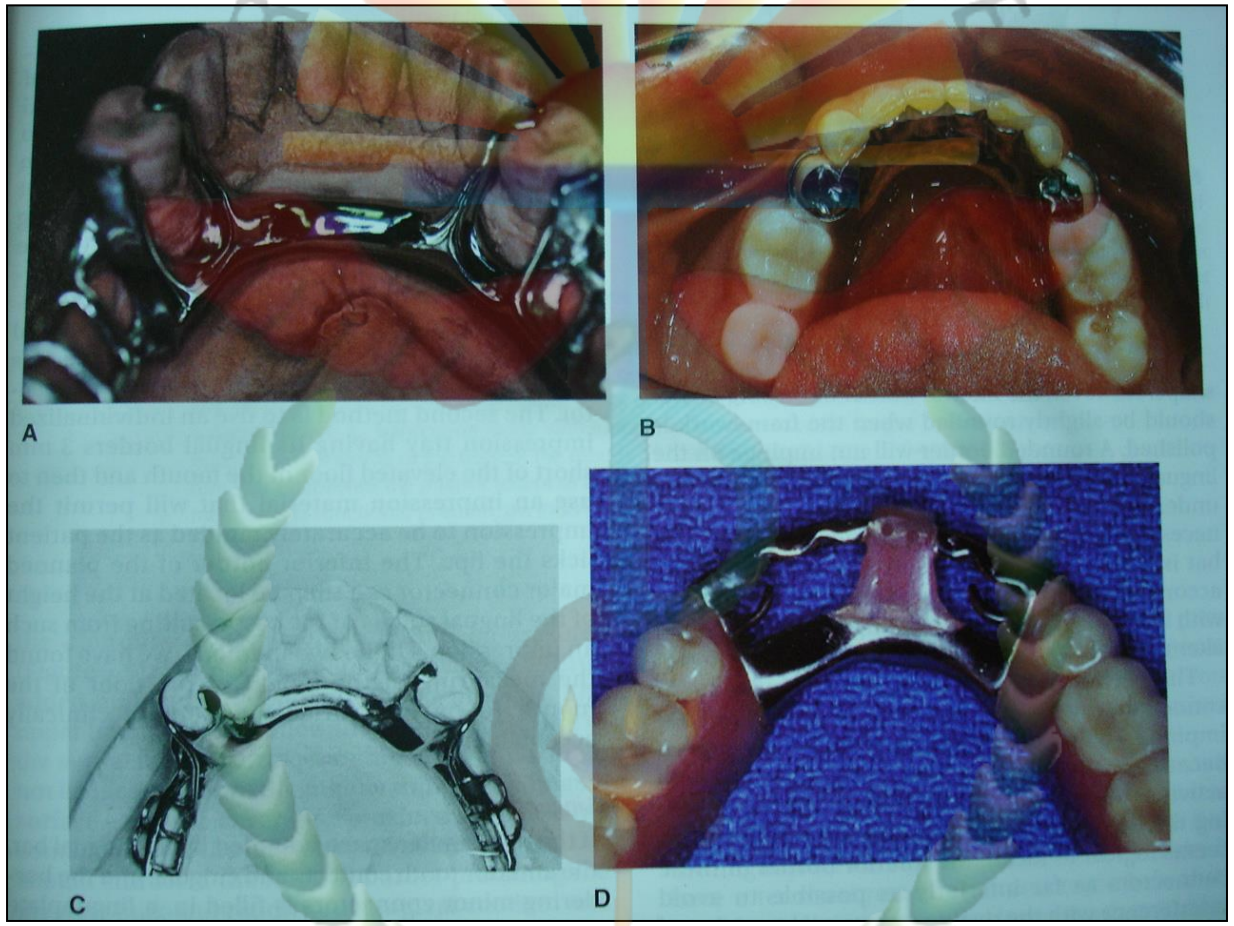

# Cingulum bar (continuous bar)

- In case of excessive interproximal blockout when using linguoplate major connector.
- Located on or slightly above the cingula of anterior teeth.

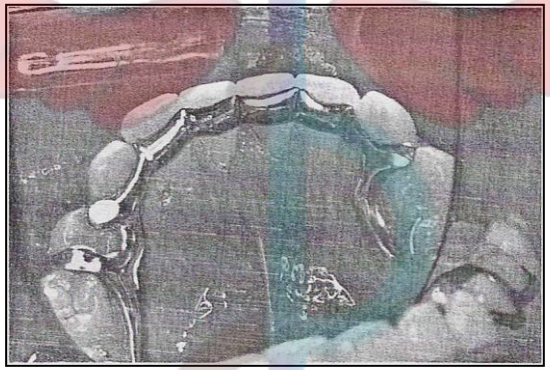

# Labial bar

- It is half pear shaped simillar to mandibular lingual bar but the thickness and hight is more
- In cases of extreme lingual inclination of the remaining lower premolar and incisor teeth prevents the use of other major connectors.
- A large mandibular tori.

cient bulk for rigidity is to be obtained. This type of major connector easily traps food and is often more objectionable to patients than a linguoplate. **B,** Cingulum bar (continuous bar) major connector. Although this design may reduce the possibility of food entrapment, it may not provide adequate rigidity.

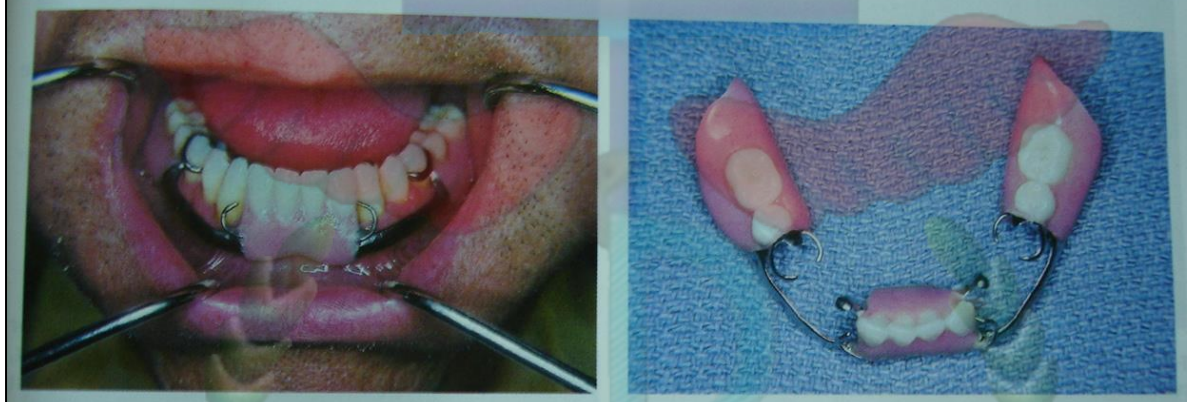

A



B

**Figure 5-15** **A,** Lingual inclination of patient's canines and premolars precludes use of lingual bar. **B,** Labial bar major connector was used in treatment. Retention was obtained on terminal abutments. Support and stabilization were gained by using rests, minor connectors arising from labial bar, and well-fitting denture bases.

Support is provided by multiple rests on the remaining natural teeth. Stabilization and reciprocation are provided by a linguoplate contacting the

1. Missing key abutments. By using all the remaining teeth for retention and stability, the absence of a key abutment (such as a canine) may not

# Design of mandibular major connector

- The systematic approach to designing a mandibular can be used.

1. Outline the basal seat areas
2. Outline the inferior border of the major connector
3. Outline the superior border of the major connector
4. Connect the basal seat area to the remaining areas

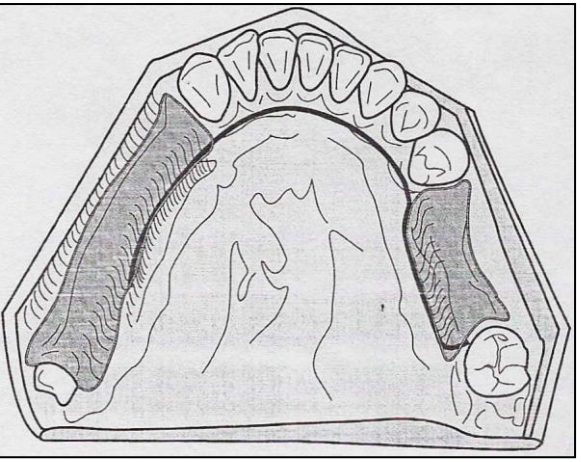

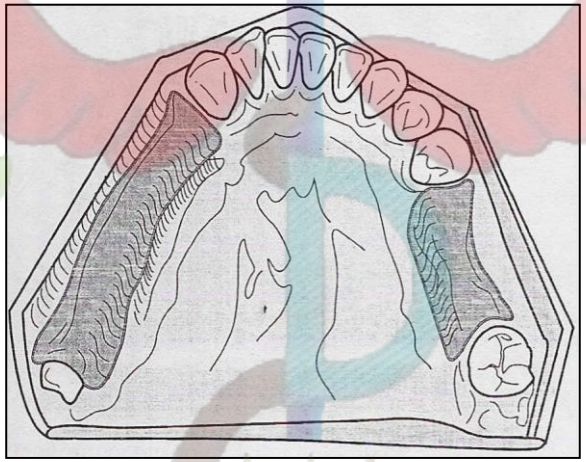

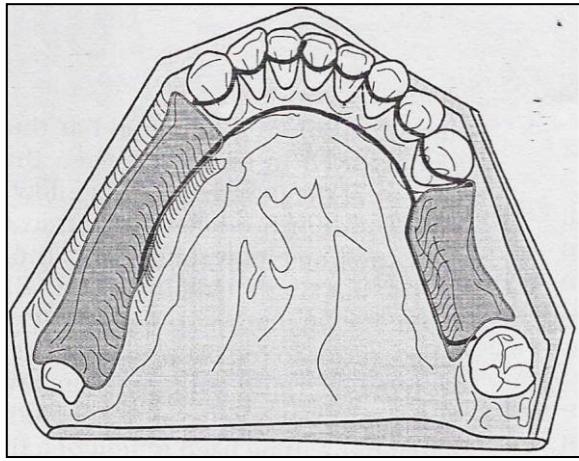

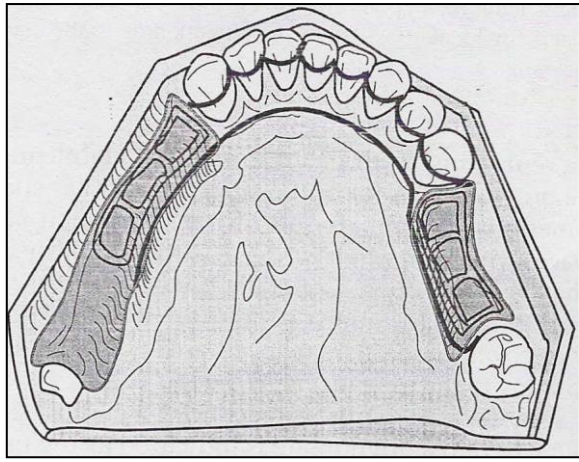

# conclusion

- although there are many variations of major connector , a thorough comprehension of all factors influencing the design will lead to the best design for each patient.

# Take away message

- Indication  of various major connectors, their advantages and disadvantages.

# probable saqs and laqs

laqs

what are major and minor connectors describe in detail mandibular major connectors

saq

functions of rest in rpd

occlusal rest and rest seat

# Thankyou