


T.P.C.T.'S
TERNA DENTAL COLLEGE


PREMOLARS

**DEPARTMENT OF ORAL PATHOLOGY
AND MICROBIOLOGY**




CONTENT

- Mandibular 2nd premolar
chronology
surfaces
conclusion




OBJECTIVE

- To help understand students anatomy of mandibular 1st and 2nd premolars.




The Permanent Mandibular Premolars

- The mandibular first premolars are developed from four lobes.
- The mandibular second premolars are, in most instances, developed from five lobes, three buccal and two lingual lobes.



- The first premolar has large buccal cusp, which is long and well formed, with a small, nonfunctioning lingual cusp.
- The first premolar is always the smaller of the two mandibular premolars.



Mandibular Second Premolar

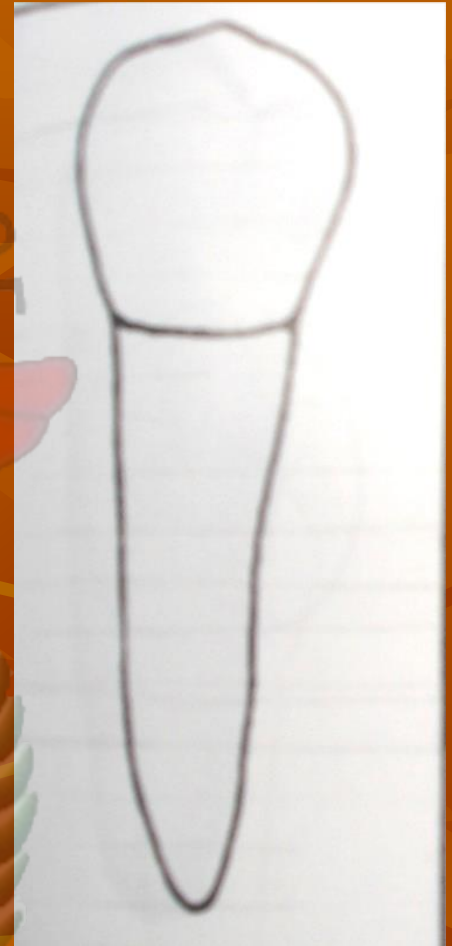
- First evidence of calcification 2 ¼ to 2 ½ Yr
 - Enamel Completed 6 to 7 Yr
 - Eruption 11 to 12 Yr
 - Root completed 13 to 14 Yr
-
- This tooth assumes two common forms. The first form, which probably occurs most often, is the **three-cusp type**, which appears more angular from the occlusal aspect. The second form is the **two-cusp type**, which appears more rounded from the occlusal aspect.

The single root of the second premolar is larger and longer than that of the first premolar.



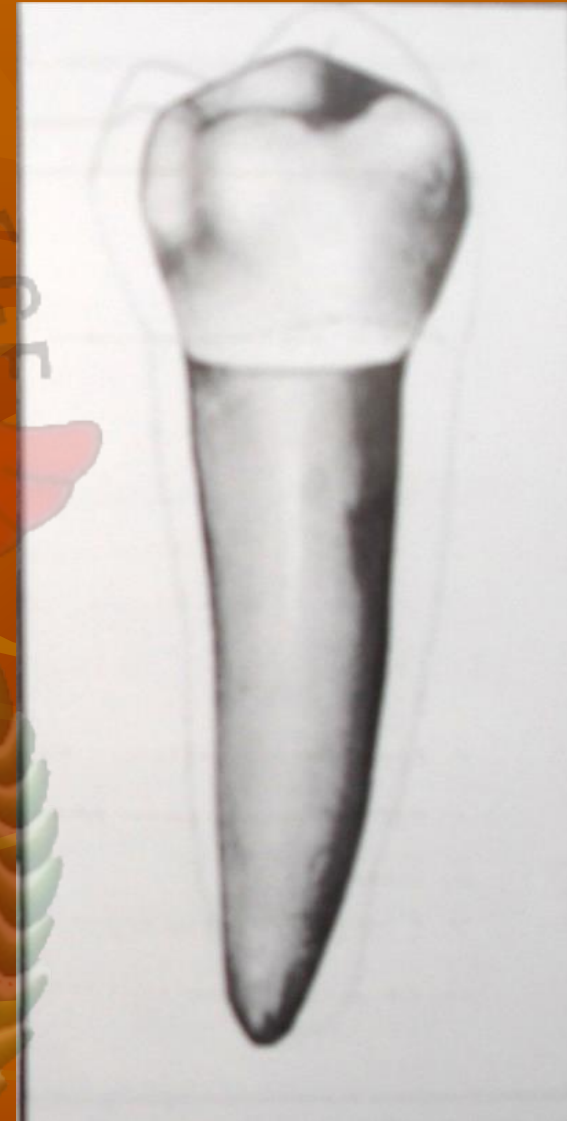Buccal Aspect

- The mandibular second premolar presents a **shorter buccal cusp** than the first premolar, with mesiobuccal and distobuccal cusp ridges presenting **angulation of less degree**.
- The contact areas, both mesial and distal, are broad. The contact areas appear to be **higher** because of the short buccal cusp.
- The **root is broader** mesiodistally than that of the first premolar, and the root ends in an apex that is more blunt.

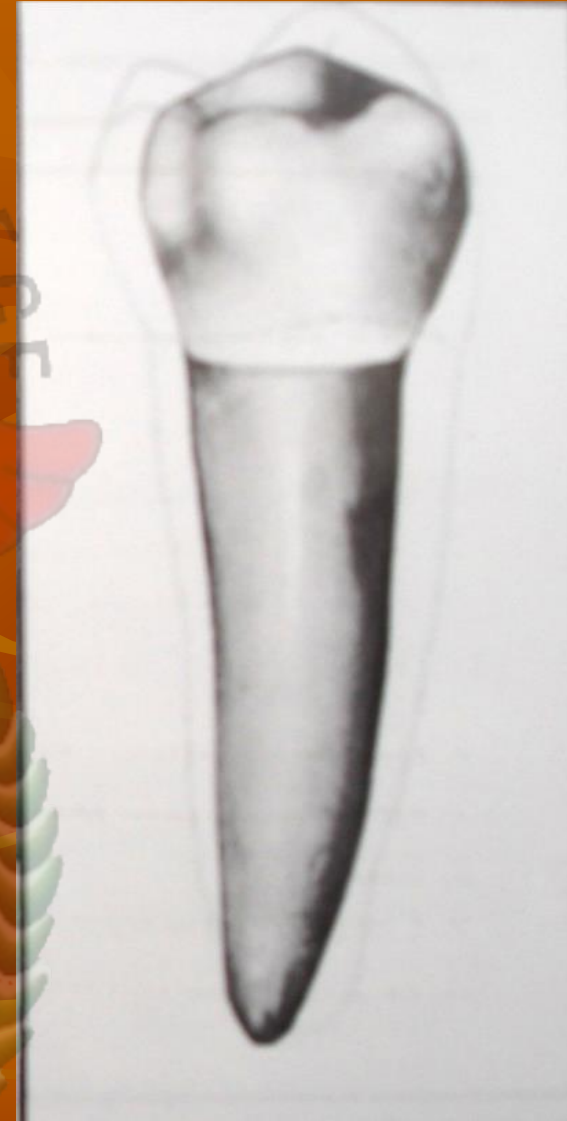


Lingual Aspect

- The lingual lobes are developed to a greater degree, making the cusp or cusps longer.
- Less of the occlusal surface may be seen from this aspect.
- In the three-cusp type, **mesiolingual and distolingual cusps** are present, with the former being the **larger and the longer one** in most cases. A groove is between them, extending a very short distance on the lingual surface and usually centered over the root.
- In the two-cusp type, the single lingual cusp development attains equal height with the three-cusp. The two-cusp type has no groove.

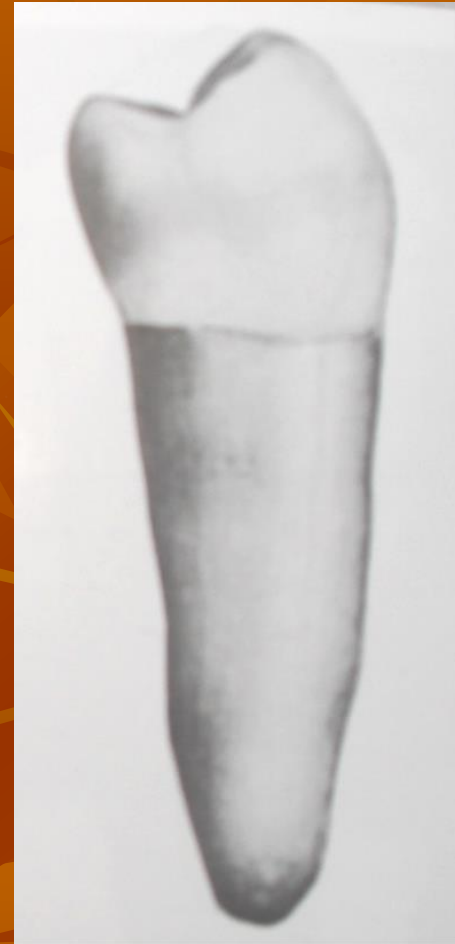

- The lingual surface of the crown is **smooth and spheroidal**, having a bulbous form above the constricted cervical portion.
- The root is wide lingually, although not quite so wide as the buccal portion.
- Less of the mesial and distal sides of the tooth may be seen from this aspect.
- The lingual portion of the root is smoothly convex for most of its length. Considered overall, the **second premolar is the larger of the two mandibular premolars.**

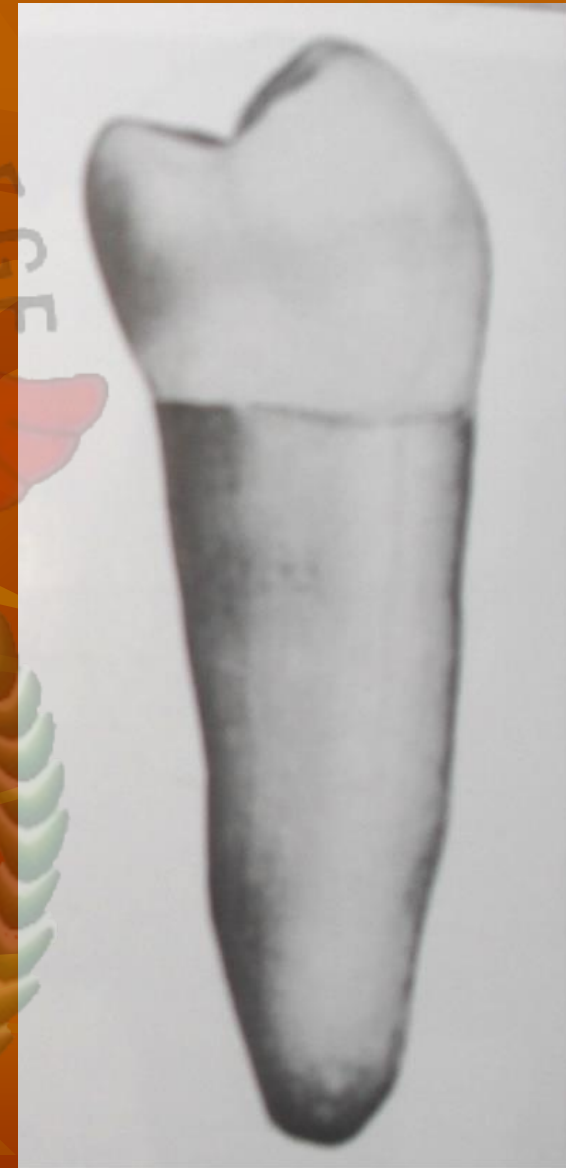


Mesial Aspect

1. The crown and root are wider buccolingually.
2. The buccal cusps is not so nearly centered over the root trunk, and it is shorter.
3. The lingual lobe development is greater.
4. The marginal ridge is at right angles to the long axis of the tooth.

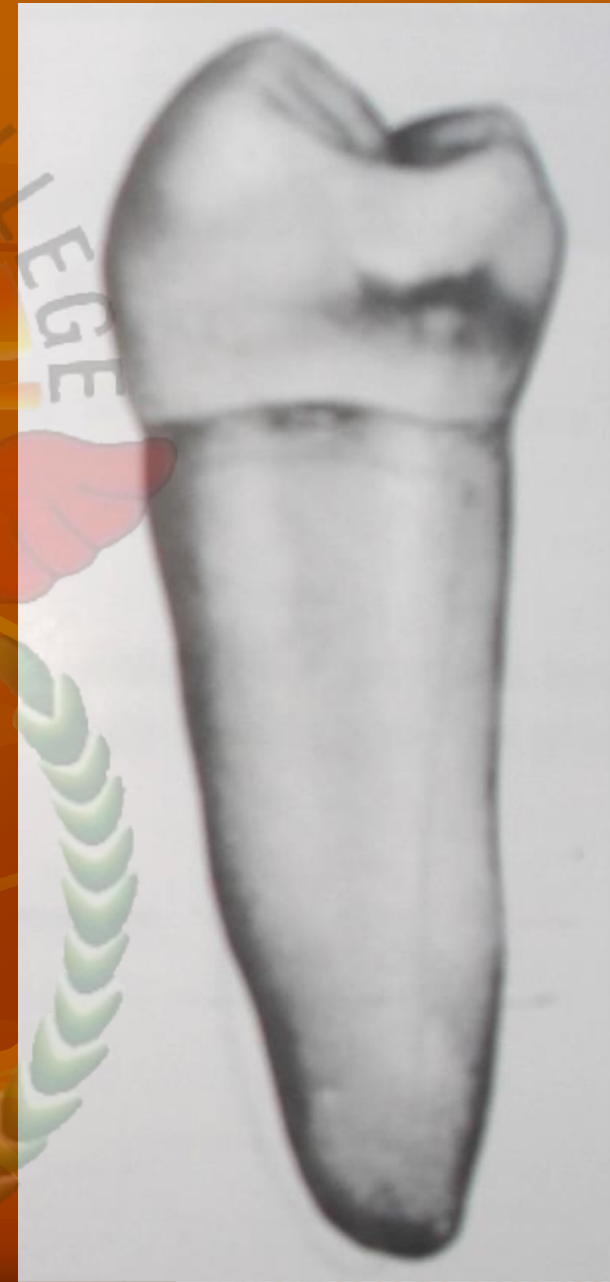

- T.P.C.T.'S
TERMA DENTAL COLLEGE
5. Less of the occlusal surface may be seen.
 6. No mesiolingual developmental groove on the crown portion.
 7. The root is longer.
 8. The apex of the root is usually more blunt on the second premolar.




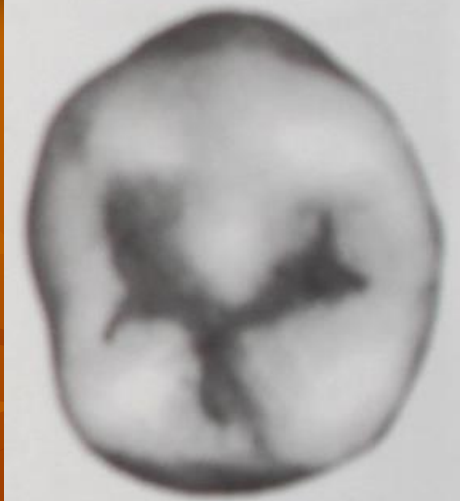
Distal Aspect

- This aspect of the mandibular second premolar is similar to the mesial aspect, except that **more of the occlusal surface may be seen** . This is possible because the **distal marginal ridge is at a lower level** than the mesial marginal ridge.
- The crowns of all posterior teeth are **tipped distally** to the long axis of the roots so that when the specimen tooth is held vertically, more of the occlusal surface may be seen from the distal aspect than from the mesial aspect.

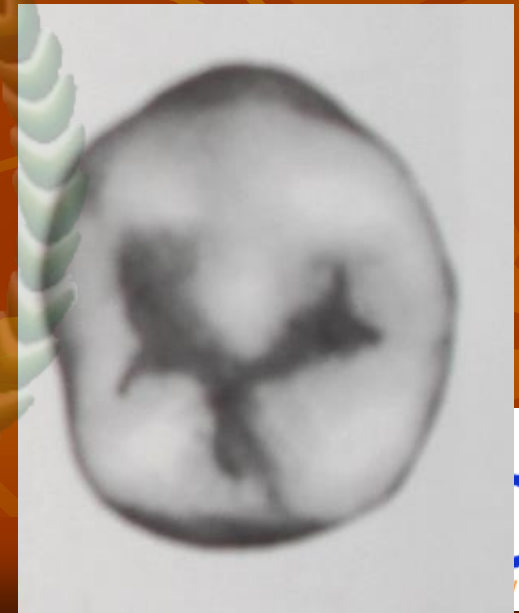


Occlusal Aspect


- The **three-cusp type** appears **square** lingual to the buccal cusp ridges when highly developed. The round or two-cusp, type appears round lingual to the buccal cusp ridges.
- The square type has three cusps that are distinct; the buccal cusps is the largest, the mesiolingual cusp is next, and the **distolingual cusp is the smallest.**



- Each cusp has well-formed triangular ridges separated by deep developmental grooves. These grooves converge in a central pit and form a **Y-shape on the occlusal surface.**
- **Supplemental groove and depression** are often seen, radiating from the developmental grooves.



- The occlusal characteristics of the two-cusp type are as follows:
 1. The outline of the crown is rounded lingual to the buccal cusp ridges.
 2. The mesiolingual and distolingual line angles are rounded.
 3. One well-developed lingual cusp is directly opposite the buccal cusp in a lingual direction.



- A central developmental groove on the occlusal surface travels in a mesiodistal direction. This groove may be straight, but it is most often **crescent-shaped**. The central groove has its terminals centered in mesial and distal fossae, supplemental grooves and depressions radiating from the central groove and its terminals.
- Some of these teeth show mesial and distal developmental pits centered in the mesial and distal fossae.


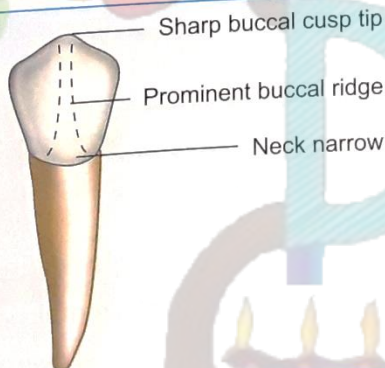
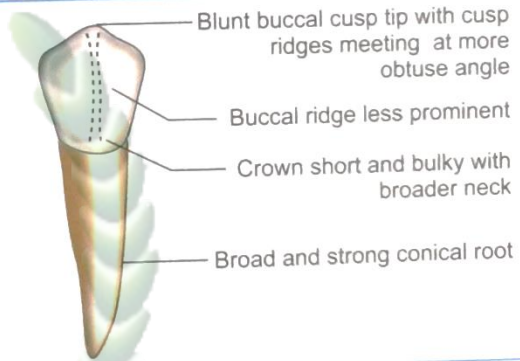
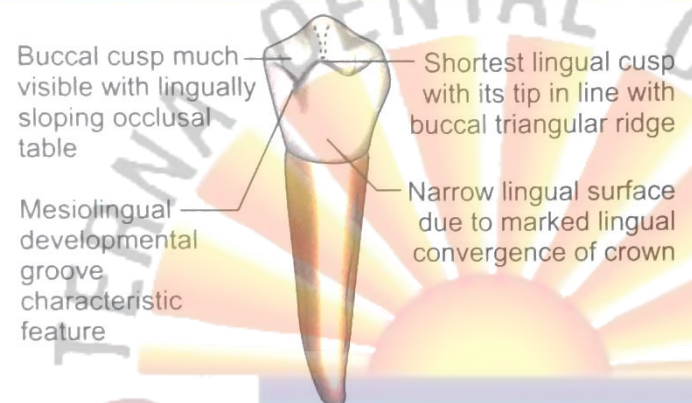
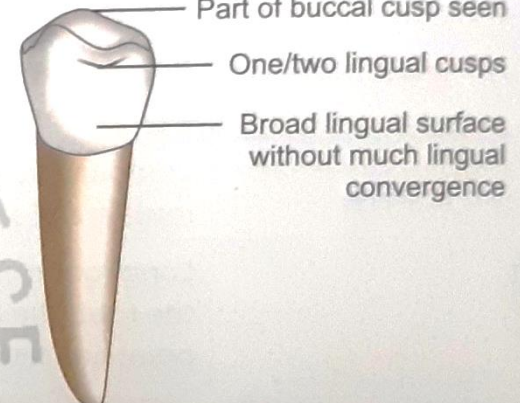


Table 17.3 Differences between mandibular 1st and 2nd permanent premolars (Mandibular premolar type traits)

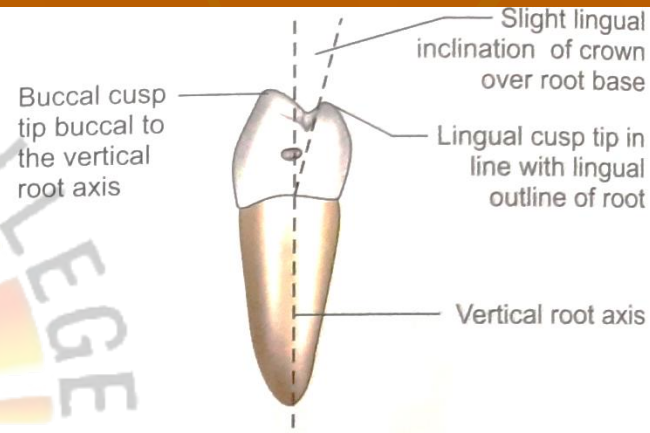
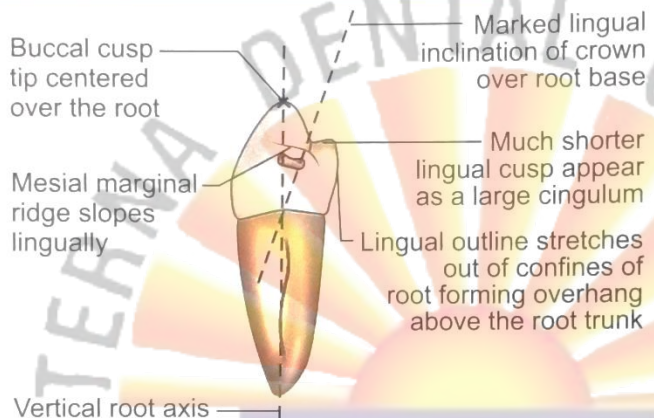
CHARACTERISTICS	MANDIBULAR 1ST PERMANENT PREMOLAR	MANDIBULAR 2ND PERMANENT PREMOLAR
Tooth nomenclature		
Universal system	Right 28, left 21	Right 29; left 20
Zsigmondy/Palmer system	Right $\overline{4}$; Left $\overline{4}$	Right $\overline{5}$; Left $\overline{5}$
FDI system	Right 44; Left 34	Right 45; Left 35
Chronology		
Developmental lobes	4 lobes, 3 labial and 1 lingual lobe Lingual lobe not well developed	5 lobes—frequently (3 labial and 2 lingual lobes) or 4 lobes Lingual lobe well developed
Eruption	10–12 years	11–12 years
Root completion	12–13 years	13–14 years
Variation in form	No much variation in form	3 cusp type or two cusp type
CROWN		
Buccal aspect		
Crown height	Longer crown	Shorter crown
Crown width	Narrow	Wider and bulky crown
Neck of the tooth	Narrow at cervix	Crown wider at cervix
Buccal ridge	More prominent	Less prominent
Contact area	Mesial contact area cervically located than distal	Distal contact area cervically located than the mesial



CHARACTERISTICS	MANDIBULAR 1ST PERMANENT PREMOLAR	MANDIBULAR 2ND PERMANENT PREMOLAR
Lingual aspect	 <p>Buccal cusp much visible with lingually sloping occlusal table</p> <p>Mesiolingual developmental groove characteristic feature</p> <p>Shortest lingual cusp with its tip in line with buccal triangular ridge</p> <p>Narrow lingual surface due to marked lingual convergence of crown</p>	 <p>Part of buccal cusp seen</p> <p>One/two lingual cusps</p> <p>Broad lingual surface without much lingual convergence</p>
Number of lingual cusps	1 lingual cusp	1 or 2 lingual cusps (Mesiolingual cusp wider than distolingual cusp)
Lingual cusp(s)	Very small, non-functional lingual cusp	Functional lingual cusp or cusps
Lingual cusp height	Very short	Nearly of same height as buccal cusp
Lingual convergence	Marked lingual convergence of crown due to small lingual cusp	Crown on lingual is as wide as buccal (Very little lingual convergence)
Visibility of buccal profile and proximal surfaces	All of buccal profile Proximal walls of crown are visible from lingual view	Only buccal cusp tip and part of proximal walls seen
Occlusal surface visibility	Most of occlusal surface visible along with buccal triangular ridge and marginal ridges	No much occlusal surface visible
Developmental grooves	<i>Mesiolingual developmental groove</i> extends from occlusal surface onto lingual surface mesially	No mesiolingual groove A short lingual developmental groove separating 2 lingual cusps may be seen (In 3 cusp type).
Lingual surface	Narrow, notched by mesiolingual groove mesially	Broad and smooth spheroidal



Mesial aspect



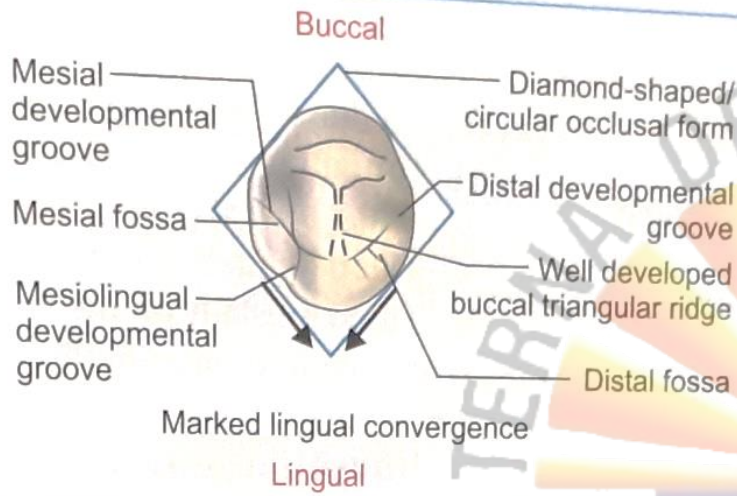
Similarity to canine	Appears similar to canine from proximal view	No similarity to canine
Lingual inclination of crown	Crown more lingually inclined on root base	Lingual tilt not so pronounced
Lingual cusp	Much shorter than buccal cusp	Lingual cusps are slightly shorter than buccal cusp
Occlusal plane	Tilted lingually due to very small lingual cusp	Horizontal, no lingual tilt
Lingual overhang on root	Lingual outline stretches out of confines of root. Creates overhang over root trunk	Lingual overhang of crown not so pronounced
<i>Marginal ridges</i>		
Length	Mesial marginal ridge is shorter than distal	Both marginal ridges of same size
Tilt	Marginal ridges lingually tilted	Marginal ridges are horizontal
Location	Mesial marginal ridge more cervically placed than distal (In general, distal marginal ridge is more cervically located in all teeth, mandibular 1st premolar is an exception)	Distal marginal ridge is more cervically placed than the mesial



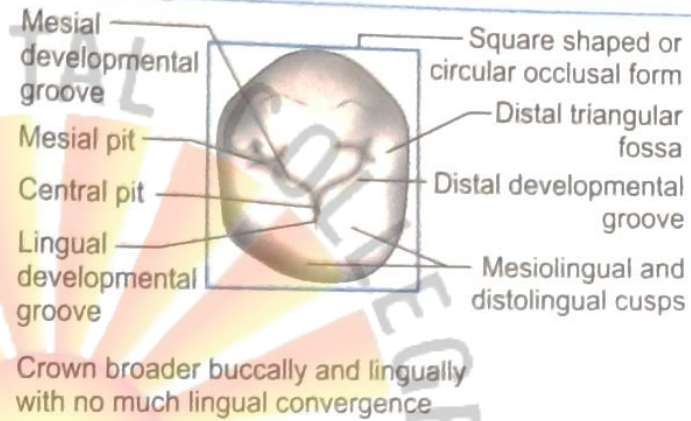
Contd...

CHARACTERISTICS	MANDIBULAR 1ST PERMANENT PREMOLAR	MANDIBULAR 2ND PERMANENT PREMOLAR
Visibility of occlusal surface	More of occlusal surface is visible from mesial aspect	More of occlusal surface visible from distal aspect
<i>Cusp tip</i>		
• Buccal cusp tip	In line with vertical root axis (centered over root base)	Buccal to the vertical root axis
• Lingual cusp tip	In line with lingual outline of root	In line with or lingual to the lingual outline of root
Proximal surfaces	Mesial surface has mesiolingual groove	Smooth
Distal aspect		
Distal marginal ridge	At higher level than mesial ridge	At lower level than mesial ridge
Cervical line	Less curved	Less curved





Less curved



Diamond shaped

Square shaped (3 cusp) circular (2 cusp type)

Small, non-functional occlusal surface

Large functional occlusal surface

Greater buccally than lingually

Nearly equal buccally and lingually
Can be wider on lingually than buccally (3 cusp type)

Because of lingual crown tilt, most of buccal surface and very little lingual surface visible from occlusal view

Less of buccal and lingual surfaces are visible

Do not vary much

Varies according to 3 cusp type or 2 cusp type

Large buccal and small non-functional lingual cusp

Buccal and 1 lingual or 2 lingual cusps (Mesiolingual and distolingual)

Present

Not present

No variability

Varies "Y" pattern—3 cusp type
"U" or "H" pattern—2 cusp type

Mesial developmental groove
Distal developmental groove
Mesiolingual developmental groove

In 3 cusp type


- Mesial developmental groove
- Distal developmental groove
- Lingual developmental groove

In 2 cusp type

- Mesial developmental groove


CONCLUSION

- An understanding of the size ,shape and dimensions of the mandibular premolars and the related anatomical differences between the two mandibular premolars.



TAKE AWAY MESSAGE

- It is important to know the anatomy of the mandibular premolars for diagnosis of any associated defects with respect to them.



T.P.C.T.'S
TERNA DENTAL COLLEGE

Thank U



MCQS

1. In the mandibular arch, in which tooth maximum lingual inclination is present _____?
A. 1st premolar
B. 3rd molar
C. Lateral incisors
D. Canine
2. Steepest cusp is seen in _____?
A. Maxillary 1st premolar
B. Maxillary 1st molar
C. Mandibular 2nd molar
D. Mandibular 1st molar
3. The premolar with the occlusal groove pattern that may simulate the letter “Y” is _____?
A. Maxillary first
B. Maxillary second
C. Mandibular second
D. Mandibular first



4. The occlusal surface shape of a 3 cusped mandibular second premolar _____?

- A. Oval
- C. Square

- B. Elliptical
- D. Tetrahedral

5. Mandibular second premolar 3- cusp type id developed from _____?

- A. 3
- B. 4
- C. 5
- D. 6

6. Difference between mandibular and maxillary premolars is that in the mandibular premolars ?

- A. The buccal and lingual cusps are more prominent
- B. The lingual cusp is sharper and longer
- C. The lingual surface rounded and less developed
- D. The buccal surface is rounded and less developed



7. Mesiolingual grooves may be found on which of the following permanent teeth _____?

- A. Mandibular second molars
- B. Mandibular first premolars
- C. Maxillary first molars
- D. Maxillary canine

8. Which of the premolars is usually the smallest _____?

- A. Maxillary first
- B. Maxillary second
- C. Mandibular first
- D. Mandibular second

9. Which of the following has a nonfunctional cusp ?

- A. Mandibular canine
- B. Maxillary second premolar
- C. Mandibular first premolar
- D. None of the above




10. The lingual cusp of lower first premolar is compared to the development of _____?

- A. Cusp of carabelli
- B. Distolingual cusp of molars
- C. Lingual cusp of second premolar
- D. Cingulum of canine



ANSWERS :

1. A 2. A 3. C 4. C 5. C 6. C 7. B 8. C 9. C 10. D



LAQ's

1. Enumerate the differences between permanent mandibular first bicuspid and permanent mandibular second bicuspid.
2. Describe the morphology of mandibular right first premolar.

SAQ's

1. Premolars.
2. Occlusal surface of permanent first premolar.
3. Difference between maxillary and mandibular first premolar.
4. Buccal and occlusal surface of mandibular second premolar.

